

heart defects that do not require this procedure. This, along with other comorbidities, could have played a role in the greater mortality observed in patients that underwent FB, and this procedure not have been the direct cause of the increase, as these patients were in poorer condition or had more severe disease at the time of surgical intervention.

The main limitations of the study, in addition to its retrospective design, are its small sample size, unavoidable given that it was conducted in a single centre, and few hospitals in Spain—to our knowledge—have published case series on the subject.

Thus, to conclude, we believe that FB may offer a high diagnostic and therapeutic yield in neonates and infants with surgically corrected congenital heart defects, and while considered an invasive technique and precisely on this account, its potential benefits and risk should be assessed on a case-by-case basis before its performance. Expert use of FB and its performance based on shared decision-making by intensive care physicians, cardiologists and bronchoscopy practitioners make this technique reasonably safe, but it is never without risk or a routine procedure. It is also important to remember potential complications, in which the underlying disease and condition of the patient at the time of the procedure play a significant role.

## References

- White S, Danowitz M, Solounias N. Embryology and evolutionary history of the respiratory tract. *Edorium J Anat Embryo*. 2016;3:54–62.
- Chen T, Qiu L, Zhong L, Tao Q, Liu H. Flexible bronchoscopy in pulmonary diseases in children with congenital cardiovascular abnormalities. *Exp Ther Med*. 2018;15:5481–6.
- Efrati O, Sadeh-Gornik U, Modan-Moses D, Barak A, Szeinberg A, Vardi A, et al. Flexible bronchoscopy and bronchoalveolar lavage in pediatric patients with lung disease. *Pediatr Crit Care Med*. 2009;10:80–4.
- Pérez-Frías J, Moreno Galdó A, Pérez Ruiz E, Barrio Gómez De Agüero MI, Escribano Montaner A, Aguilera P. Pediatric bronchoscopy guidelines. *Arch Bronconeumol*. 2011;47:350–60.
- Pérez Ruiz E, Milano Manso G, Pérez Frías J. La fibrobroncoscopia en el niño con ventilación mecánica. *An Pediatr (Barc)*. 2003;59:462–90.
- Shah BK, Sachdev A. Use of flexible bronchoscopy in children with congenital heart disease: a 5 year experience. *Chest*. 2019;155:235.
- Paradis TJ, Dixon J, Tieu BH. The role of bronchoscopy in the diagnosis of airway disease. *J Thorac Dis*. 2016;8:3826–37.

M. Carmen López Castillo<sup>a,b,\*</sup>, Laura Fernández Carretero<sup>c</sup>, Antonio Morales Martínez<sup>d</sup>, Almudena Ortiz Garrido<sup>e</sup>, Pilar Caro García<sup>f</sup>

<sup>a</sup> Unidad de Gestión Clínica de Neonatología, Hospital Regional Universitario de Málaga, Málaga, Spain

<sup>b</sup> Facultad de Medicina, Universidad de Málaga, Málaga, Spain

<sup>c</sup> Unidad de Gestión Clínica de Pediatría, Hospital Regional Universitario de Málaga, Málaga, Spain

<sup>d</sup> Unidad de Gestión Clínica de Cuidados Críticos Pediátricos y Urgencias, Hospital Regional Universitario de Málaga, Málaga, Spain

<sup>e</sup> Unidad de Gestión Clínica de Pediatría, Servicio de Cardiología Pediátrica, Hospital Regional Universitario de Málaga, Málaga, Spain

<sup>f</sup> Unidad de Gestión Clínica de Pediatría, Servicio de Neumología, Hospital Regional Universitario de Málaga, Málaga, Spain

\* Corresponding author.

E-mail address: [mcarmen.lopez123@gmail.com](mailto:mcarmen.lopez123@gmail.com) (M.C. López Castillo).

<https://doi.org/10.1016/j.anpede.2021.01.009>

2341-2879/ © 2022 Asociación Española de Pediatría. Published by Elsevier España, S.L.U. This is an open access article under the CC BY-NC-ND license (<http://creativecommons.org/licenses/by-nc-nd/4.0/>).

## Current perspectives in Ross and Ross–Konno procedures: Is it time to search for alternatives?<sup>☆,☆☆</sup>



### Perspectivas actuales en el procedimiento de Ross y Ross–Konno: ¿es hora de buscar alternativas?

Dear Editor:

Congenital left ventricular outflow tract obstruction that is symptomatic or associated with ventricular dysfunction is

an indication for surgery in the paediatric population. When the obstruction is at the level of the aortic valve, the Ross procedure (pulmonary autograft) is the approach of choice. When the obstruction is found at several levels, the gold standard is the Ross-Konno procedure (pulmonary autograft combined with ventriculoseptoplasty). Both techniques have shown to provide excellent haemodynamic outcomes and potential for growth.<sup>1</sup>

However, none of these alternatives can be considered a definitive solution when the problem arises in neonates or infants.<sup>2,3</sup> Outcomes in the medium to long term show a substantial number of reinterventions, both percutaneous and surgical. When both sides of the heart are involved, treatment becomes very complex.

A new possibility for these patients has recently emerged with the description of the Ozaki technique<sup>4</sup> (complete aortic valve reconstruction using pericardial tissue). To be able to make meaningful comparisons in the future, the outcomes of techniques currently in use need to be analysed first. For this reason, we report our experience in the last decade using the gold standard techniques.

<sup>☆</sup> Please cite this article as: Aroca Á, Polo L, Ramchandani B, Sánchez R, González Á. Perspectivas actuales en el procedimiento de Ross y Ross-Konno: ¿es hora de buscar alternativas? *An Pediatr (Barc)*. 2022;96:365–367.

<sup>☆☆</sup> This study was presented at the XXV National Congress of the Sociedad Española de Cirugía Cardiovascular y Endovascular, held online between October 14–17, 2020.

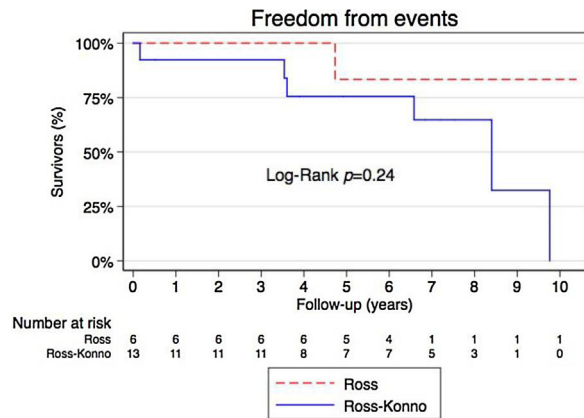
**Table 1** Preoperative variables.

Preoperative variables	Ross (n = 6)	Ross-Konno (n = 15)	P
Age in months, median (IQR)	97.5 (84–144)	60 (4–115)	.10
Weight in kg, median (IQR)	27 (18.5–38.7)	15 (4,7–27)	.094
Height in cm, median (IQR)	124.5 (115–153)	112 (55–138)	.14
Number of previous surgeries			.027
0	5	3	
1	0	6	
2	1	6	
Number of previous percutaneous procedures:			
0			
1	3	9	.37
2	3	2	
3	0	3	
	0	1	
Aortic annulus diameter in mm, median (IQR)	17.5 (15–19)	12 (5.6–17)	.023
Peak aortic pressure gradient in mmHg, median (IQR)	55 (21–70)	90 (70–115)	.035
Mean aortic pressure gradient in mmHg, median (IQR)	31 (13–45)	48 (36–64)	.067
Indication for surgery			
Aortic stenosis	2	4	.26
Aortic insufficiency	1	0	
Double aortic lesion	3	11	

A total of 21 procedures (6 Ross/15 Ross-Konno) were performed between 2008–2019. Two in-hospital deaths were documented, both in the Ross-Konno group and caused by a failed aortic valvuloplasty in the neonatal period. Both of these patients required postoperative extracorporeal membrane oxygenation (ECMO). One of these patients was successfully weaned out, but later developed necrotising enterocolitis. The median aortic annulus diameter and age of surgery was significantly lower in the Ross-Konno group compared to the Ross group: 12 mm (interquartile range [IQR], 5.6–17) versus 17.5 mm (IQR, 15–19) and 60 months (IQR, 4–115) versus 97.5 months (IQR, 84–144). The number of previous surgeries and the hours of mechanical ventilation were significantly greater in the Ross-Konno group (Table 1).

There were no losses to follow-up, with a median duration of follow-up of 6.2 years (IQR, 5.9–6.5) in the Ross group versus 5.3 years (IQR, 3.6–7.2) in Ross-Konno group. There were 2 deaths, both associated with surgical reintervention. In 1 case, reintervention consisted of a right ventricle to pulmonary artery (RV-PA) conduit replacement with tricuspid valvuloplasty in a patient that had undergone the Ross-Konno procedure 9 years before. Before the surgery, the right ventricle was severely compromised, and the patient died 2 months post surgery due to multiple organ failure. In the second case, the death was not related to the Ross-Konno surgery, but resulted from thrombosis of a mechanical mitral valve prosthesis. This patient had hypoplastic left heart complex with a history of 5 prior surgeries, and had undergone the Ross-Konno procedure 7 months before the development of the valve thrombosis.

The 3-, 5- and 7-year event-free survival was 100%, 83% and 83%, respectively, in the Ross group and 92%, 76% and 65%, respectively, in the Ross-Konno group,



**Figure 1** Event-free survival (death and/or reintervention) during the follow-up in both groups.

with no statistically significant differences between groups (Fig. 1).

During the follow-up, 7 patients (37%) needed some form of reintervention (surgical and/or percutaneous): 1 in the Ross group (17%) and 6 in the Ross-Konno group (46%). Most of the reinterventions were related to RV-PA conduit dysfunction.

The late haemodynamic outcomes are good, especially the outcomes of autografts, none of which required reintervention on the aortic valve or the autograft. All patients had mild or no residual aortic regurgitation (AR), except 2 patients in the Ross group (33%), 1 with moderate AR and 1 with severe AR, but both with good left ventricular function, and 1 patient with severe AR in the Ross-Konno group that also had good left ventricular function. As for the right heart, all survivors had mild or no pulmonary regurgitation (PR), except 2 patients in the Ross-Konno

group that had severe PR but good RV function, and 1 patient in the Ross group and 1 in the Ross-Konno group with moderate PR.

There are considerable limitations to our study due to its retrospective design and small sample size. However, we believe that our findings are relevant, as there are few reports of the medium- and long-term outcomes of these procedures in the paediatric age group. We believe that sharing our results provides information on clinical experiences that may contribute to a better understanding of this disease.

In conclusion, due to the complex nature of these procedures, postoperative complications are frequent. They achieve good solutions for the left ventricle outflow tract obstructions in the medium-to-long term, but at the expense of multiple RV-PA conduit reinterventions. The experience with the Ozaki technique is still limited to 4.5 years, but it is less aggressive, as it does not require manipulation of the right side of the heart (the pulmonary autograft is not needed).<sup>5,6</sup> The initial experience in 6 patients with a 15-month follow-up shows promising results. Only time will tell whether this new technique will replace the current gold standard.

## References

1. Piccardo A, Ghez O, Gariboldi V, Riberi A, Collart F, Kreitmann B, et al. Ross and Ross–Konno procedures in infants, children and adolescents: a 13 year experience. *J Heart Valve Dis.* 2009;18:76–83.
2. Mookhoek A, Charitos EI, Hazekamp MG, Bogers AJJC, Hörer J, Lange R, et al. Ross procedure in neonates and infants: a European multicenter experience. *Ann Thorac Surg.* 2015;100:2278–85.
3. Sames-Dolzer E, Wickenhauser E, Kreuzer M, Benedikt P, Gitter R, Prandstetter C, et al. The Ross–Konno procedure in neonates and infants less than 3 months of age. *Eur J Cardiothorac Surg.* 2018;54:71–7.
4. Ozaki S, Yamashita H, Uchida S, Takatoh M, Kiyohara N. Midterm outcomes after aortic valve neocuspidization with glutaraldehyde-treated autologous pericardium. *J Thorac Cardiovasc Surg.* 2018;155:2379–87.
5. Wiggins LM, Mimic B, Issitt R, Ilic S, Bonello B, Marek J, et al. The utility of aortic valve leaflet reconstruction techniques in children and young adults. *J Thorac Cardiovasc Surg.* 2020;159:2369–78.
6. Baird CW, Sefton B, Chávez M, Sleeper LA, Marx GR, del Nido PJ. Congenital aortic and truncal valve reconstruction utilizing the ozaki technique: short-term clinical results. *J Thorac Cardiovasc Surg* [Internet]. 2020. Feb. Available from: <https://linkinghub.elsevier.com/retrieve/pii/S0022522320304384>

Ángel Aroca, Luz Polo, Bunty Ramchandani\*, Raúl Sánchez, Álvaro González  
*Departamento de Cirugía Cardíaca Pediátrica, Hospital Universitario La Paz-Hospital Universitario Ramón y Cajal, Madrid, Spain*

\* Corresponding author.

E-mail address: [bunty.r@gmail.com](mailto:bunty.r@gmail.com) (B. Ramchandani).

30 November 2020 7 December 2020

<https://doi.org/10.1016/j.anpede.2021.02.003>  
 2341-2879/ © 2021 Published by Elsevier España, S.L.U. on behalf of Asociación Española de Pediatría. This is an open access article under the CC BY-NC-ND license (<http://creativecommons.org/licenses/by-nc-nd/4.0/>).

## Do neonatologists in Spain offer an interview with parents during pregnancy? National survey<sup>☆,☆☆</sup>



### ¿Asesoramos los neonatólogos en España a los padres durante el embarazo? Encuesta nacional

Dear Editor,

The emotional impact on parents of the diagnosis of an anomaly in the foetus during pregnancy merits reflection. During this stage, neonatologists have the opportunity to carry out a prenatal intervention by conducting an inter-

view with the family to answer any questions and start the shared decision-making process. This prenatal consultation has potential benefits and is also a challenge for clinicians,<sup>1</sup> who must have the necessary communication skills to adapt the conversation to fit the needs of the parents, empower them in decision-making and provide emotional support.<sup>2</sup> However, at present there is little evidence to guide prenatal counselling when disease is diagnosed in the foetus, although there are some published works devoted to it in the context of prematurity.<sup>1,3–5</sup>

With the primary objective of determining whether neonatologists in Spain offer families an interview during the pregnancy if foetal disease is detected, we carried out a nationwide survey. As secondary objectives, we assessed whether the care level of the unit was associated with the probability of offering a prenatal interview and whether residents in paediatrics received specific training on this subject.

We developed an *ad hoc* questionnaire, as we did not find any validated instruments that fit the area of interest of the study. We distributed the questionnaire in 2019 through Google<sup>®</sup> Forms to 167 hospitals with neonatal units throughout Spain.

Sixty-six percent of surveyed facilities participated in the study (N = 110). Of this total, 83% were public hospitals, and

<sup>☆</sup> Please cite this article as: López González MF, Vela Enríquez F, García Martín R, Vargas Pérez M. ¿Asesoramos los neonatólogos en España a los padres durante el embarazo? Encuesta nacional. *An Pediatr (Barc).* 2022;96:367–369.

<sup>☆☆</sup> **Previous presentation:** this study was presented at the XXVII Congress of Neonatology and Perinatal Medicine, October 3–4, 2019, Madrid, Spain. Session of oral communications of research projects to apply for full membership in the Sociedad Española de Neonatología.