



IMAGES IN PAEDIATRICS

Uncovering ischemic stroke: The heart as key

Descubriendo el accidente cerebrovascular isquémico: EL corazón como clave

Joana Afonso Neto^{a,b,*}, Catarina Almeida^c, Joana Lima^d, Raquel Sousa^{a,b,e}^a *Servicio de Pediatría, Centro Hospitalar Universitário São João, Oporto, Portugal*^b *Facultad de Medicina, Universidad de Oporto, Oporto, Portugal*^c *Servicio de Cardiología Pediátrica, Centro Hospitalar Universitário São João, Oporto, Portugal*^d *Servicio de Neurorradiología, Unidad Local de Salud Matosinhos, Oporto, Portugal*^e *Unidad de Neuropediatría, Centro Hospitalar Universitário São João, Oporto, Portugal*

Received 3 June 2025; accepted 9 September 2025

Available online 9 January 2026

Male adolescent aged 16 years with presenting complaint consisting of a 15-minute episode of loss of consciousness, facial and upper limb involuntary movements and urinary incontinence followed by excessive somnolence.

The findings of initial tests, including bloodwork, toxicology, head CT and lumbar puncture, were unremarkable. The patient then developed right-sided hemiparesis with homonymous hemianopia and aphasia (score of 9 on the Pediatric NIH Stroke Scale [PedNIHSS]). A cerebral CT angiogram revealed an embolic ischemic stroke resulting from the occlusion of the M2 segment of the left middle cerebral artery. The etiological evaluation revealed a large left atrial mass (Fig. 1), which was surgically excised and confirmed as a myxoma in the histological analysis.

After surgery, the patient started treatment with aspirin (100 mg/day) and underwent structured motor and speech rehabilitation. Follow-up MRI scans (Figs. 2 and 3) showed stable ischemic lesions with no evidence of recurrent embolism. At present, the patient exhibits mild right hemi-

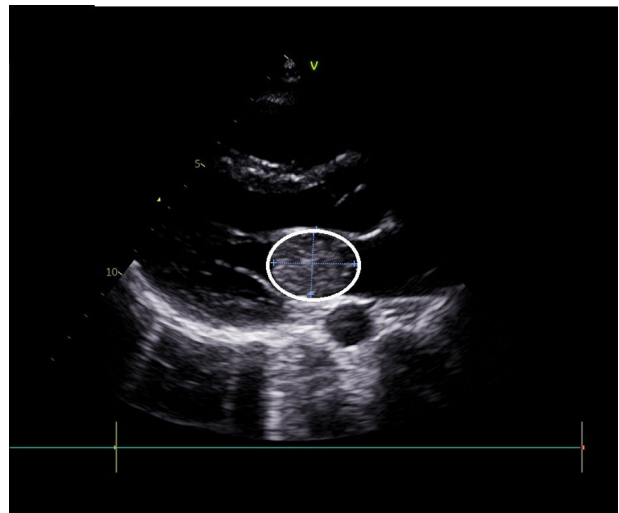


Figure 1 Echocardiogram showing left atrial myxoma (white circle) measuring 33 mm × 27 mm.

paresis, nominal aphasia (score of 5 on the PedNIHSS) and slight behavioral changes.

The management of pediatric stroke is challenging on account of atypical presentations and a broad differential

DOI of original article:

<https://doi.org/10.1016/j.anpedi.2025.504081>

* Corresponding author.

E-mail address: joananeto940@hotmail.com (J.A. Neto).

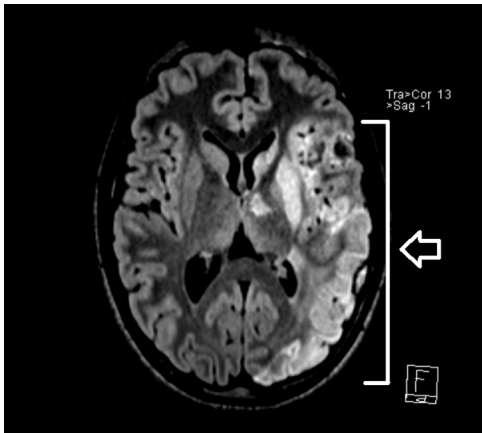


Figure 2 Axial 3D-FLAIR image showing the extent of the ischemic stroke (white arrow).

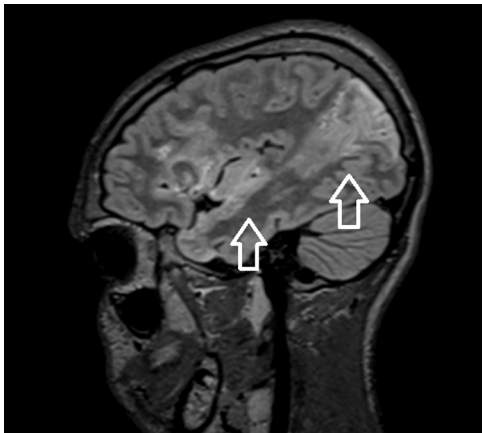


Figure 3 Sagittal 3D-FLAIR image showing the extent of the ischemic stroke (white arrow).

diagnosis that includes seizures, migraine and vasculitis. Brain MRI is essential for accurate diagnosis. The role of reperfusion therapy, anticoagulation or antithrombotic strategies in children is unclear, given the limited evidence and lack of pediatric trials. Standardized protocols are essential for determining eligibility, guiding treatment and minimizing complications. This case highlights how performance of imaging and a comprehensive evaluation at an early stage is important to prevent recurrence and improve outcomes.^{1,2}

References

1. Ise H, Ishikawa N, Nakanishi S, Kamiya H. Giant left atrial myxoma causing acute ischemic stroke in a child. *Surg Case Rep.* 2018;4(1):6, <http://dx.doi.org/10.1186/s40792-017-0411-2>. PMID: 29330629; PMCID: PMC5766478.
2. Alguizzani N, Alomair M, Halawa S, Aljughiman M. Pediatric cardiac myxoma: a rare cause of stroke in a six-year-old child. *World J Pediatr Congenit Heart Surg.* 2024;15(5):675–7, <http://dx.doi.org/10.1177/21501351241245336>. Epub 2024 May 16. PMID: 38752225.