



## SCIENTIFIC LETTER

## Percutaneous shunt closure in patients with nickel allergy<sup>☆</sup>



### Cierre percutáneo de shunts en pacientes alérgicos al níquel

Dear Editor:

Percutaneous closure of percutaneous ostium secundum atrial septal defect or patent ductus arteriosus with devices containing nickel has become common practice due to its safety and effectiveness.<sup>1,2</sup> However, given that up to 15% of the general population may be allergic to nickel,<sup>3,4</sup> it would be prudent to adopt approaches that minimise the contact of nickel with blood to prevent potential systemic hypersensitivity reactions. We now proceed to describe a successful experience with closure of patent ductus arteriosus (PDA) and atrial septal defect (ASD) with Occlutech™ devices in 2 patients with known nickel allergy. These devices have a thin coating of titanium oxide that reduces blood exposure to nickel and could be an appropriate and safe alternative for intervention in patients with nickel allergy.

The patients were a girl aged 10 years with patent ductus arteriosus and a girl aged 8 years with ostium secundum ASD. The families reported an allergic skin reaction to costume jewellery, so the patients underwent epicutaneous tests to rule out nickel allergy, with positive results in both cases. Two months before interventional heart catheterization, each of the patients was tested for nickel allergy by placement of different percutaneous vascular closure devices on the anterior thorax and the abdomen (Fig. 1a), affixed to the skin with Mefix adhesive dressing tape (Fig. 1b). The patient with PDA was tested with the Amplatzer Septal Occluder (ASO™) and the Occlutech PDA Occluder™, while the patient with ASD was tested with the ASO™, the Gore Septal Occluder™, the Figulla ASD Occluder™ and the Cardia Ultrasept™. Neither patient developed cutaneous or systemic reactions in 72 h of exposure.

The devices used for percutaneous closure of PDA and ASD were the Occlutech PDA Occluder™ 3.5/5 (Occlutech International AB; Helsingborg, Sweden) and the Figulla Flex II ASD Occluder™ 16.5 mm (FFO, Occlutech GmbH; Jena, Germany), respectively, both of which were implanted without complications (Fig. 2).

Both devices are self-expanding and made of nitinol (an alloy of 55% nickel and 45% titanium), which confers pseudoelasticity and shape memory. They are also coated with a thin layer of titanium oxide that reduces exposure to nickel. Both patients remained asymptomatic 3 years after the procedure.

In current clinical practice, most patients that are allergic to nickel with intracardiac or extracardiac shunts are treated with devices that contain nickel.<sup>3</sup> However, a potential inflammatory response to the nitinol contained in the device could cause platelet aggregates or the secretion of inflammatory mediators that could then be distributed through the body by the systemic circulation.<sup>1,2</sup> Although most patients remain asymptomatic after percutaneous closure of the defect, clinical manifestations of nickel allergy may develop immediately or months later. The clinical presentation is heterogeneous, and may range from a simple skin rash, fever, migraine, difficulty breathing or chest pain to massive pericardial bleeding with cardiac tamponade.<sup>1–4</sup> The symptoms may resolve spontaneously or require steroid therapy, and in some cases the device ultimately needs to be removed.<sup>2,5</sup>

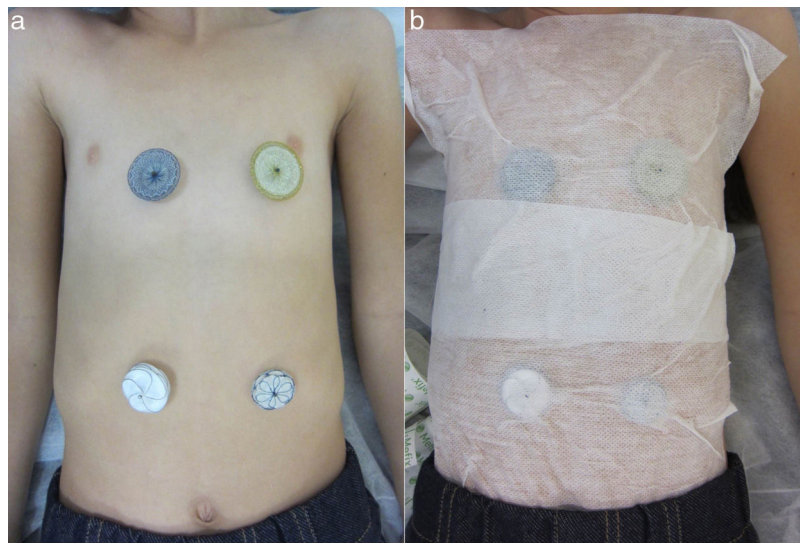
Nickel allergy can be assessed before percutaneous closure by means of epicutaneous tests.<sup>2</sup> In case of positive results with a local skin reaction, closure should be performed with devices with a lower nickel content or designed to reduce exposure to nickel.<sup>3</sup> Although the patients whose cases we describe here had positive epicutaneous test results for nickel allergy, neither developed cutaneous reactions to the devices.

The current literature shows disagreement as to the appropriate approach to a patient allergic to nickel that requires a percutaneous closure device containing nitinol. While some authors consider that it is important to take the allergy into account before planning percutaneous closure with nickel-containing devices, others believe that this is a minor issue.<sup>6</sup>

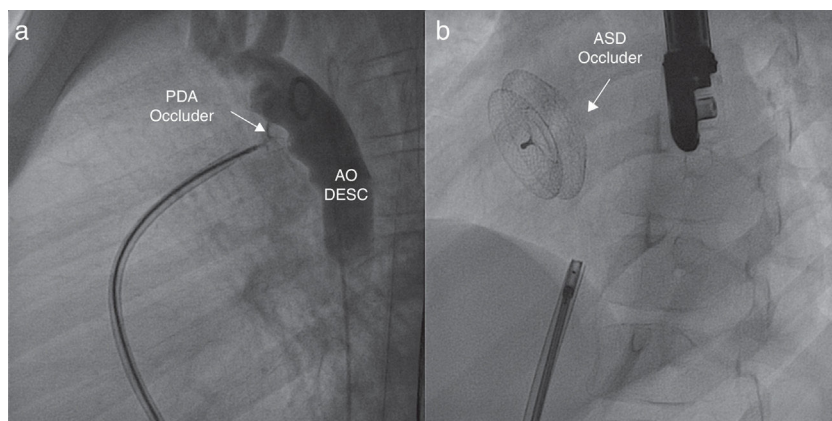
To date, different approaches have been proposed in case of suspected nickel allergy. Some authors have mentioned Helix devices as a good alternative, as they contain a minimal amount of exposed nickel.<sup>4</sup> Lertsapcharoen et al. have described a self-expanding nitinol device coated in platinum for percutaneous ASD closure.<sup>6</sup> Cammalleri et al. reported the successful use of the Atriasept II, a device with a lower content of nitinol compared to most other devices, for closure of patent ductus arteriosus in 4 patients with severe nickel allergy.<sup>3</sup>

It would be reasonable to rule out nickel allergy before percutaneous implantation of devices containing this material to prevent a potential systemic hypersensitivity reaction. In patients with nickel allergy, testing by

<sup>☆</sup> Please cite this article as: Figueras-Coll M, Sabaté-Rotés A, Martí-Aguasca G, Roguera-Sopena M, Betrián-Blasco P. Cierre percutáneo de shunts en pacientes alérgicos al níquel. An Pediatr (Barc). 2020;92:102–104.



**Figure 1** (a) Photograph of the anterior region of the thorax and the abdomen demonstrating the lack of cutaneous reactions after contact with different percutaneous ASD closure devices: Amplatzer Septal Occluder (top left); Figulla ASD Occluder (top right); Cardia Ultrasept (bottom left) and Gore Septal Occluder (bottom right). (b) Photograph illustrating the method used to affix the devices to the skin.



**Figure 2** (a) Right anterior oblique angiogram showing the Occlutech PDA occluder (arrow). The contrast infused from the descending aorta evinces the absence of a residual shunt through the patent ductus arteriosus. AO DESC: descending aorta. (b) Anteroposterior fluoroscopy view that shows the ASD closure device, the Figulla ASD Occluder (arrow), after its release.

direct contact of the skin with the percutaneous devices under consideration to detect skin or systemic reactions and to guide the selection of the device that will be ultimately implanted can be useful. In our opinion, devices with a smaller nickel content or reduced exposure to nickel should be selected in case of known nickel allergy. In this context, Occlutech™ devices, which are coated with a thin layer of titanium oxide, have proven effective and safe.

## References

1. Wertman B, Azarbal B, Tobis J. Adverse events associated with nickel allergy in patients undergoing percutaneous atrial septal defect or patent foramen ovale closure. *J Am Coll Cardiol.* 2006;47:1226–7.
2. Spina R, Muller DW, Jansz P, Gunalingam B. Nickel hypersensitivity reaction following Amplatzer atrial septal defect occluder device deployment successfully treated by explantation of the device. *Int J Cardiol.* 2016;223:242–3.
3. Cammalleri V, Ussia GP, Marchei M, Muscoli S, Sergi D, Macrini M, et al. Percutaneous closure of patent foramen ovale with Atrisept II device in nickel allergic patients. *J Cardiovasc Med (Hagerstown).* 2014;15:350–2.
4. Reddy BT, Patel JB, Powell DL, Michaels AD. Interatrial shunt closure devices in patients with nickel allergy. *Catheter Cardiovasc Interv.* 2009;74:647–51.
5. Verma SK, Tobis JM. Explantation of patent foramen ovale closure devices: a multicenter survey. *JACC Cardiovasc Interv.* 2011;4:579–85.
6. Lertsapcharoen P, Khongphatthanayothin A, Srimahachota S, Lee-lanukrom R. Self-expanding platinum-coated nitinol devices for transcatheter closure of atrial septal defect: prevention of nickel release. *J Invasive Cardiol.* 2008;20: 279–83.

Marc Figueras-Coll <sup>a,b,\*</sup>, Anna Sabaté-Rotés <sup>b</sup>,  
Gerard Martí-Aguasca <sup>a</sup>, Marc Roguera-Sopena <sup>c</sup>,  
Pedro Betrián-Blasco <sup>a,b</sup>

<sup>a</sup> *Unidad de Hemodinámica Pediátrica, Servicio de  
Pediatria, Hospital Universitari Vall d'Hebron, Universitat  
Autònoma de Barcelona, Barcelona, Spain*

<sup>b</sup> *Unidad de Cardiología Pediátrica, Servicio de Pediatria,  
Hospital Universitari Vall d'Hebrón, Universitat Autònoma  
de Barcelona, Barcelona, Spain*

<sup>c</sup> *Unidad de Cardiología Pediátrica, Servicio de Pediatria,  
Hospital Universitario Germans Trias y Pujol, Universitat  
Autònoma de Barcelona, Badalona, Spain*

\* Corresponding author.

E-mail address: [mfiguerascoll@gmail.com](mailto:mfiguerascoll@gmail.com)

(M. Figueras-Coll).

2341-2879/ © 2019 Published by Elsevier España, S.L.U. on behalf  
of Asociación Española de Pediatría. This is an open access article  
under the CC BY-NC-ND license ([http://creativecommons.org/  
licenses/by-nc-nd/4.0/](http://creativecommons.org/licenses/by-nc-nd/4.0/)).

## Glucose and galactose malabsorption: A new case in Spain<sup>☆</sup>



### Malabsorción de glucosa y galactosa. Nuevo caso en España

Dear Editor:

Congenital diarrhoea refers to a heterogeneous group of enteropathies that cause symptoms from the first few days of life, and it may be the only manifestation or one of the symptoms of a systemic disease. In most cases, early treatment is necessary to prevent dehydration, given the potential complications of the latter. The first step in the differential diagnosis is to differentiate between secretory and osmotic diarrhoea: in the former, the diarrhoeal output does not improve with a nil per os trial, whereas in the latter it does.<sup>1</sup>

We present the case of a male newborn aged 2 days admitted to the neonatal unit with hyperbilirubinaemia. The parents were Pakistani and reported consanguinity. The newborn was a product of a monochorionic-diamniotic twin pregnancy and had been born second at 36 weeks' gestation with a weight of 2460 g. He was receiving artificial formula following the wishes of the mother. On admission to the neonatal unit, the physical examination revealed a 15% weight loss, jaundice extending to Kramer's zone 3 and a dry oral mucosa, with no other abnormal findings. Blood tests revealed hyperbilirubinaemia on account of elevation of indirect bilirubin and dehydration with hypernatraemia and hyperchloraemia (urea, 49 mg/dL; creatinine, 1.5 mg/dL; sodium, 163 mEq/L; chloride, 132 mEq/L) and metabolic acidosis (pH, 7.30; bicarbonate, 18.7 mM; base excess, 7 mM; lactate, 3.9 mM). Phototherapy was initiated, along with placement of a peripheral catheter for intravenous fluid replacement, while the patient continued to receive artificial formula. The diarrhoeal output continued to be very high, leading to prescription of nil per os, which achieved resolution of the diarrhoea. The analysis of stool samples revealed an acidic pH and the presence of reducing

bodies. In the following days, several attempts were made to reintroduce oral feedings, first with elemental formula and later with a soy-based formula, with diarrhoea recurring in both instances as the feeding volume increased. Eventually, the newborn was given a fructose-based formula with no other carbohydrates, to which he responded favourably. Increases in feeding volume did not create problems, and the boy started producing normal stools and exhibiting adequate weight gain.

In this case, since the patient improved with fasting, the diarrhoea was classified as osmotic, and the presence of reducing bodies in the stool suggested that the congenital diarrhoea could be due to carbohydrate malabsorption. Since the patient did not improve with the soy formula, we suspected glucose-galactose malabsorption,<sup>1</sup> as soy formulas do not contain galactose but do contain glucose. In fact, upon switching to a formula in which the sole carbohydrate was fructose, the newborn responded well, which supported our clinical suspicion.

Congenital glucose-galactose malabsorption (cGGM) is a rare autosomal recessive disorder characterised by changes in the *SLC5A1* gene that encodes the protein SGLT1, responsible for transporting glucose and galactose from the intestinal lumen into intestinal cells.<sup>2</sup> Sequencing of this gene in the patient revealed the homozygous mutation c.875G>A (p.C292Y), previously described as a pathogenic variant, as it impacts the location and function of the protein,<sup>3</sup> thus confirming the diagnosis. Microsatellite genotyping confirmed that the twins were dizygotic, which explained the clinical differences between the two.

Congenital glucose-galactose malabsorption is characterised by severe diarrhoea and dehydration from the first day of life, which can quickly result in the death of the infant if glucose, galactose and the disaccharides that contain them are not removed from the diet.<sup>4</sup> Approximately 300 cases have been diagnosed worldwide.<sup>5</sup> Treatment consists in the elimination of glucose and galactose from the diet, substituting a fructose-based formula, which achieves resolution of diarrhoea. Some authors have proposed that cGGM improves over time as the intestinal flora adapts, and it appears that administration of *Lactobacillus acidophilus* helps shorten the time that carbohydrates need to be restricted.<sup>6</sup> However, there are no prospective studies in the literature establishing how to identify which patients will develop tolerance and which will remain intolerant for life, so we currently recommend that older children and

<sup>☆</sup> Please cite this article as: Lodoso-Torrecilla B, Perez de Nanclores G, Garin I, Calvo-Saez A, Martínez-Fernández de Pinedo I. Malabsorción de glucosa y galactosa. Nuevo caso en España. *An Pediatr (Barc)*. 2020;92:104-105.