

^a Servicio de Urgencias Pediátricas, Hospital Universitario La Paz, Madrid, Spain

^b Servicio de Pediatría, Hospital Universitario de Fuenlabrada, Fuenlabrada, Madrid, Spain

^c Servicio de Urgencias Pediátricas, Hospital Universitario La Paz, Madrid, Spain

^d Servicio de Pediatría, Hospital Universitario de Getafe, Getafe, Madrid, Spain

^e Unidad de Endocrinología y Diabetes Pediátrica, Servicio de Pediatría, Hospital Universitario Ramón y Cajal, Madrid, Spain

* Corresponding author.

E-mail address: malacatin@hotmail.com

(M.Á. Molina Gutiérrez).

¹ Appendix A lists the members of the Research Group on Urgent Paediatric Endocrinological Diseases.

<https://doi.org/10.1016/j.anpede.2022.05.006>

2341-2879/ © 2022 Asociación Española de Pediatría. Published by Elsevier España, S.L.U. This is an open access article under the CC BY-NC-ND license (<http://creativecommons.org/licenses/by-nc-nd/4.0/>).

Treatment for acquired aplasia and refractory cytopenia. Review of a historical cohort[☆]



Tratamiento de la aplasia adquirida y la citopenia refractaria. Revisión de una cohorte histórica

Dear Editor:

Recently, we reviewed the experience in our hospital in the management of acquired aplastic anaemia (AAA) and refractory cytopenia in childhood (RCC), in accordance with the recommendations and studies associated with the a European Society for Blood and Marrow Transplantation (EBMT).^{1,2} Acquired aplastic anaemia is the most common form of acquired bone marrow failure, with an estimated incidence of 1.5 cases per 2 million individuals per

year in Europe.¹ Refractory cytopenia in childhood is the most common myelodysplastic syndrome in children. It is recommended that these patients receive the same treatment established for AAA, based on haematopoietic stem cell transplantation (HSCT) or immunosuppressive therapy (IST).³ The aim of our study was to retrospectively assess the response rate, event-free survival and overall survival of patients with AAA and RCC that underwent HCST or IST.

The study included 48 patients with a diagnosis of AAA or RCC managed at the Hospital Infantil Universitario Niño Jesús between 2001 and 2020. Two patients (4.08%) did not received treatment, one due to spontaneous recovery and the other due to paroxysmal nocturnal haemoglobinuria (PNH) clone expansion, which did not require treatment until the patient was transferred to another centre. We defined complete remission (CR) as a neutrophil count of $1.5 \times 10^9/L$ or greater, a platelet count of $150 \times 10^9/L$ or greater and a haemoglobin concentration of 10.5–13 g/dL.¹ We defined partial remission (PR) as the achievement of transfusion independence. The events taken into account

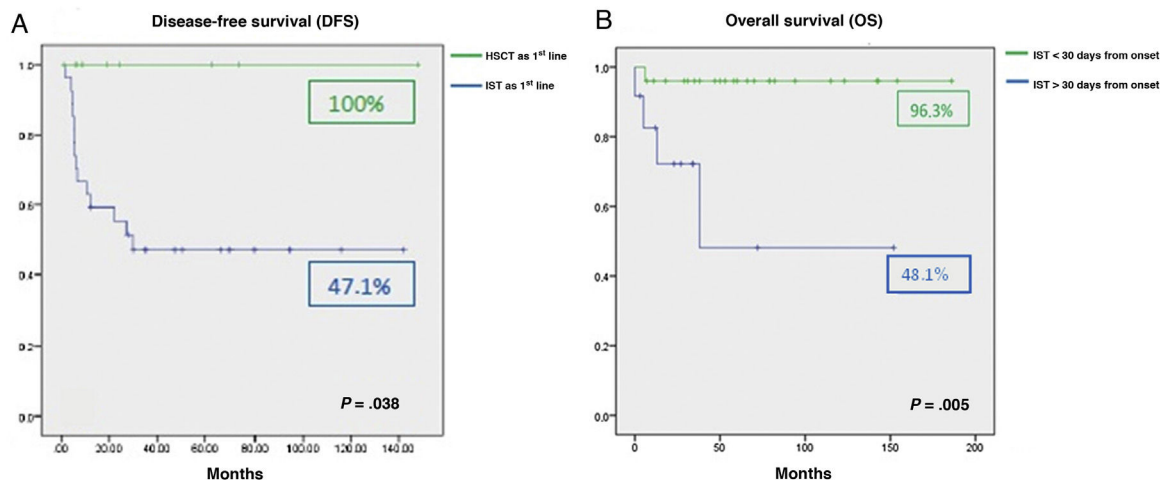


Figure 1 (A) Disease-free survival in the cohort following first-line treatment. (B) Overall survival after immunosuppressive therapy depending on the time elapsed from diagnosis to treatment.

[☆] Previous presentations: This study was presented in the LXIII National Congress of the Sociedad Española de Hematología y Hemoterapia and the xxxvii National Congress of the Sociedad Española de Trombosis y Hemostasia, held in 2021 in Pamplona, Spain.

Table 1 Characteristics of the total cohort of patients and their treatment.

N	48
Age at diagnosis (years)	11 (8–14)
Median duration of follow-up (months)	36 (13–79)
Sex	
Male (%)	33 (69%)
Female (%)	15 (31%)
Diagnosis	
Acquired aplasia (%)	33 (68.8%)
RCC (%)	15 (31.3%)
IST as first-line, total (%)	37 (77.08%)
ATGAM (%)	21 (43.75%)
Thymoglobulin (%)	16 (33.33%)
Severe neutropenia	21 (56.7%)
Transfusion dependence	24 (68.8%)
Spontaneous remission	1 (2.08%)
Progression to PNH	1 (2.08%)
HSCT, total (%)	20 (41.6%)
HSCT as first-line (HLA-identical related donor) (%)	9 (18.75%)
HSCT > first line (%)	11 (22.91%)
Conditioning	
Myeloablative	5 (25%)
Reduced toxicity	15 (75%)
Outcome of patients that underwent HSCT	
No GvHD	14 (70%)
Acute GvHD	5 (25%)
Chronic GvHD	1 (5%)
In complete remission (%)	16 (80%)
Deceased (%)	4 (20%)
Outcomes of patients treated with IST	
In complete remission (%)	17 (35.4%)
In treatment with CsA (%)	7 (18.9%)
Posterior HSCT (%)	11 (29.7%)
Death during IST (%)	1 (2.7%)
Lost to follow-up (%)	1 (2.7%)

Ranges given as Q1-Q3.

ATGAM, equine anti-thymocyte immune globulin; CMV, human cytomegalovirus; CsA, cyclosporine A; GvHD, graft versus host disease; HLA, human leukocyte antigen; HSCT, haematopoietic stem cell transplantation; IST, immunosuppressive therapy; PNH, paroxysmal nocturnal haemoglobinuria; RCC, refractory cytopenia in childhood.

in the analysis of event-free survival (EFS) were relapse and death. We used Kaplan-Meier survival analysis to generate cumulative incidence curves and compared the results by means of the log-rank test.

We found an overall survival (OS) in the case series of 90.6%. The 9 patients (18.75%) that underwent HLA-matched related donor HSCT achieved CR without requiring further treatment. In the remaining 37 patients (77.08%), IST was used for first-line treatment with a response rate of 73% (18/37 CR and 9/37 PR). Comparing the outcomes of initial treatment, we found that the OS with HSCT was 100% compared to 85% with IST as first-line treatment ($P = .321$). The comparison of HSCT versus IST for first-line treatment did

find a significant difference when it came to EFS: 100% with HSCT as first-line treatment compared to 47.1% with IST ($P = .038$) (Fig. 1A). The response rate in the 13 patients that required additional courses of IST was 61.5% (4/13 CR and 4/13 PR). The EFS with HSCT as second-line treatment was 62.5% compared to 50% with IST as second-line treatment. Of the 5 patients that did not respond to the second course of IST, 3 received transplants from alternative donors, which achieved an increase of OS with IST as second-line treatment to 83.9%. The median time elapsed from diagnosis and initiation of IST as first-line treatment was 23 days (0–180). The analysis of the association of different factors with OS in these patients showed a negative correlation of the time elapsed to initiation of the first course of IST with OS. A delay in treatment initiation of more than 30 days from diagnosis had a significant impact on treatment outcomes (96.3% vs 48.1%; $P = .005$) (Fig. 1B).

The results of our study show that the OS achieved with first-line treatment can be considered optimal, with poorer outcomes in terms of EFS. Our findings were consistent with those of previous case series.^{4–6} One third of the patients in our series did not require allogeneic transplantation and could be rescued with IST in the absence of an HLA-identical related donor. We also found that HSCT as second-line treatment was a good salvage therapy option after 1 course of IST, with a survival greater than 60%. We ought to highlight that the outcomes found in different groups and lines of treatment should not be interpreted with the aim of improving treatment selection, as the retrospective design of this case series only allows the description of what happened with each line of treatment as opposed to an applicable comparison (Table 1).

At present, the appropriateness of using HSCT for first-line treatment of these patients independently of the type of donor available is being investigated due to the excellent outcomes observed in patients managed with this approach, as was the case in our series with treatment with HLA-matched related donor HSCT. However, we think it is important to take into account that as many as a third of the patients may achieve a cure with IST alone. Although it may be even more important to underscore that, if IST is used as first-line treatment, it should be initiated within 30 days of diagnosis to avoid a negative impact on its outcomes.

References

- Solano Vercet C, Vázquez López L, Sanz Caballer J, García Cadenas I, Sánchez-Ortega Sánchez I, Salameo García O, GrupoEspañol de Trasplante Hematopoyético y Terapia Celular (GETH), et al. Guía para el diagnóstico y el tratamiento de las insuficiencias medulares. Madrid: SEHH, SEHOP; 2019.
- Bacigalupo A, Brand R, Oneto R, Bruno B, Socié G, Passweg J, et al. Treatment of acquired severe aplastic anemia: bone marrow transplantation compared with immunosuppressive therapy-The European Group for Blood and Marrow Transplantation experience. *Semin Hematol.* 2000;37(1):69–80.
- Locatelli F, Strahm B. How I treat myelodysplastic syndromes of childhood. *Blood.* 2018;131(13):1406–14.
- Dufour C, Pillon M, Passweg J, Socié G, Bacigalupo A, Franceschetto G, et al. Outcome of aplastic anemia in adolescence: a survey of the Severe Aplastic Anemia Working Party of the European Group for Blood and Marrow Transplantation. *Haematologica.* 2014;99(10):1574–81.

5. Pulsipher MA, Lehmann LE, Bertuch AA, Sasa G, Olson T, Nakano T, et al. A study assessing the feasibility of randomization of pediatric and young adult patients between matched unrelated donor bone marrow transplantation and immune-suppressive therapy for newly diagnosed severe aplastic anemia: a joint pilot trial of the North American Pediatric Aplastic Anemia Consortium and the Pediatric Transplantation and Cellular Therapy Consortium. *Pediatr Blood Cancer*. 2020;67(10):e28444.
6. Forester CM, Sartain SE, Guo D, Harris MH, Weinberg OK, Fleming MD, et al. Pediatric aplastic anemia and refractory cytopenia: a retrospective analysis assessing outcomes and histomorphologic predictors. *Am J Hematol*. 2015;90(4):320–6.

Jesús González de Pablo, Cristina Jiménez Cobo, Daniel Azorín Cuadrillero, Marta González-Vicent, Julián Sevilla*

Hospital Infantil Universitario Niño Jesús, Madrid, Spain

* Corresponding author.

E-mail address: julian.sevilla@salud.madrid.org (J. Sevilla).

13 January 2022 26 April 2022

<https://doi.org/10.1016/j.anpede.2022.08.006>

2341-2879/ © 2022 Published by Elsevier España, S.L.U. on behalf of Asociación Española de Pediatría. This is an open access article under the CC BY-NC-ND license (<http://creativecommons.org/licenses/by-nc-nd/4.0/>).

Gray platelet syndrome, more than just a bleeding disorder



Síndrome de plaquetas grises, algo más que un trastorno hemorrágico

Dear Editor:

Gray platelet syndrome (GPS) rare inherited bleeding disorder characterized by macrothrombocytopenia and reduction of α -granules in platelets and in megakaryocytes, which results in the presence hypogranular platelets with a grey appearance in blood smears. Affected patients present with bleeding diathesis, progressive myelofibrosis and splenomegaly. The exact prevalence of GPS is unknown, and approximately 60 cases have been reported worldwide to date.¹

The syndrome is caused by a homozygous or compound heterozygous variant in the *NBEAL2* (3p21) gene that encodes the neurobeachin-like 2 protein (NBEAL2), a member of a family of proteins containing Beige and Chediak-Higashi (BEACH) domains believed to be involved in vesicle trafficking and critical for the development of α granules.²

We describe the case of a boy aged 22 months referred for assessment of mild thrombocytopenia detected in a routine blood test. The patient was in follow-up in the otorhinolaryngology department due to enlargement of the adenoids and tonsils that caused snoring and sleep apnoea/hypopnoea. The had been born to term following in vitro fertilization (egg donation).

The salient findings of the physical examination were adenoid facies and mouth breathing, snoring and breathing difficulty when awake, obstructive tonsillar hypertrophy, hepatomegaly with a liver diameter of 3 cm, splenomegaly with a spleen diameter of 4 cm and bilateral cervical lymphadenopathy.

Due to the significant impairment resulting from the obstruction of the upper airway, the patient was admitted to hospital for monitoring of apnoeic episodes and treatment optimization, including use of continuous positive airway pressure until the patient underwent an adenotonsillectomy.

The laboratory tests revealed thrombocytopenia (90 000 platelets/mm³; mean platelet volume, 12 fL), with normal white blood cell, haemoglobin, coagulation and platelet aggregation results, and the blood smear evinced anisothrombocytopenia and hypogranular platelets. The measurement of immunoglobulins evinced a minimal elevation of IgG, chiefly on account of IgG1, and persistent elevation of vitamin B12 (maximum, 2763 pg/mL). The quantitative lymphocyte panel revealed a CD3+TCR $\alpha\beta$ CD4–CD8–percentage of 1.6% (normal range, <2%), an inverted CD4/CD8 ratio, a CD325+/CD3DR+ ratio of 0.9 (normal range >1) and a memory B cell percentage of 10% (decreased). The workup was expanded with a bone marrow aspiration due to the presence of cytopenia, adenopathy and organomegaly, and the bone marrow analysis did not find evidence of infiltration, haemophagocytosis, myelofibrosis or storage diseases.

Next-generation sequencing (NGS) was also performed with a panel that included genes involved in hereditary cytopenias and immunodeficiencies, leading to the detection of a compound heterozygous variant in the *NBEAL2* gene (NM_010575.2:c.5497G>A, p.[E1833K] and NM_010575.2:c.3592C>T, p.[Q1198*]), compatible with GPS. Carrier status was later confirmed in the father.

During the course of disease, the patient experienced recurrence of tonsillar hypertrophy and new episodes of parotitis that required treatment with anti-inflammatory drugs and, in some instances, antibiotherapy. The patient has yet to develop bleeding diathesis. The splenomegaly remained stable, and the hepatomegaly resolved and was absent at the time of this writing. When it comes to hepatomegaly, its presence, detected at admission, did not seem to be directly related to GPS and was associated with mononucleosis syndrome.

Gray platelet syndrome is a rare inherited platelet disorder characterised by the marked deficiency or absence of α -granules, which contain compounds essential for coagulation, inflammation, wound healing and other processes. Clinically, patients exhibit moderate thrombocytopenia and bleeding diathesis of varying severity. Examination of blood smears reveal enlarged agranular platelets with a grey appearance. In our patient, the records occasionally reported hypogranular platelets, but not clearly described as agranular or having a grey hue. The rarity of this disease hinders its diagnosis based on features observed in